American Journal of Case Reports

e-ISSN 1941-5923
© Am J Case Rep, 2019; 20: 1874-1878
DOI: 10.12659/AJCR.919545

Received: 2019.08.20
Accepted: 2019.10.10
Published: 2019.12.15

Neonate Death Due to Marijuana Toxicity to the Liver and Adrenals

Authors' Contribution:
Study Design A
Data Collection B
Statistical Analysis C
Data Interpretation D
Manuscript Preparation E
Literature Search F
Funds Collection G

ABCDEF Connie Bao
ABCDEFG Shiping Bao

Champaign County Coroner's Office, Urbana, IL, U.S.A.

Corresponding Author: Connie Bao, e-mail: conniewbao@gmail.com
Conflict of interest: None declared

Patient: Female, 11-day-old
Final Diagnosis: Extensive necrosis and hemorrhage of the liver and adrenals due to maternal use of marijuana
Symptoms: Unresponsiveness • vomitting
Medication: Marijuana
Clinical Procedure: —
Specialty: Pediatrics and Neonatology

Objective: Unusual clinical course
Background: Marijuana is the considered the most widely available and used drug across the world. Up to this time, there have been no reports of human death directly caused by acute marijuana toxicity in adults, fetuses, or newborn neonates.
Case Report: We report a death of an 11-day-old white female neonate due to acute marijuana toxicity. She died of extensive necrosis and hemorrhage of the liver and adrenals due to maternal use of marijuana.
Conclusions: This case is unique in that other possible causes of death can be eliminated. With growing use of marijuana by pregnant women and increases in newborn drug screening of umbilical cord homogenate, more cases of neonatal death due to acute marijuana toxicity could be discovered.

MeSH Keywords: Autopsy • Infant, Newborn • Marijuana Abuse • Pregnancy Complications • Death

Full-text PDF: https://www.amjcaserep.com/abstract/index/idArt/919545

Indexed in: [PMC] [PubMed] [Emerging Sources Citation Index (ESCI)] [Web of Science by Clarivate]

Background

Marijuana is the most widely available and used drug across the world. According to the United Nations Office on Drugs and Crime (UNODC), up to 4% of the global adult population have used marijuana in their life. In the United States alone, 11% of adults used marijuana at least once in their past. In addition, the therapeutic use of marijuana and its derivatives is increasing and has been evaluated for various health conditions including pain, anorexia, side effects of chemotherapy, multiple sclerosis, and muscle spasms [1].

The National Academies of Sciences, Engineering, and Medicine conducted a rapid turn-around comprehensive review of recent medical literature on the health effects of cannabis and cannabinoids. The committee searched more than 24 000 articles and considered over 10 700 abstracts to determine the therapeutic effects of marijuana [2]. They concluded that marijuana has conclusive or substantial therapeutic effect on chronic pain, chemotherapy-induced nausea and vomiting, and spasticity associated with multiple sclerosis. There is moderate evidence of effect on sleep disturbance, and limited evidence of effect on appetite and weight gain, post-traumatic stress disorder, anxiety, and Tourette syndrome. There is no or insufficient evidence of effect on cancer, epilepsy, neurodegenerative disorders, and irritable bowel syndrome [2].

Up to this time, there have been no reports of human death directly caused by acute marijuana toxicity [1,3,4]. There is indirect effect of marijuana use on human death due to motor-vehicle accidents, falls or other personal injuries, or suicidal behavior. There is inconclusive chronic effect on mental health, lung cancer, cardiorespiratory diseases, or cognitive impairment. There is no increased risk of human death caused by acute marijuana toxicity even for high levels of marijuana use compared to non-users [4].

The growing popularity of marijuana in the United States propels an urgent need to better understand the potential repercussions of marijuana use on maternal and fetal health during pregnancy. Research efforts are now focusing on identifying how marijuana may influence pregnancy outcomes [5]. Marijuana is believed to be the most commonly used dependent substance during pregnancy, with reported rates estimated between 2% and 11% of gravidae [6]. Many studies have been substantially limited by self-reporting data collection, recall bias, and confounding risk factors [5]. One recent epidemiology study revealed that among women with a positive umbilical cord homogenate for marijuana use, only 6.7% self-reported marijuana use [7].

Many recent epidemiology studies about maternal marijuana use, adverse pregnancy outcomes, and neonatal morbidity are inconclusive [5–11]. These studies were not able to separate indirect maternal physical or mental effects on the fetus from direct toxicity of marijuana on the fetus or newborn neonate. After extensive search of peer-reviewed publications and online data, there are no reports found of fetal or neonatal death directly caused by acute marijuana toxicity. No reports proposed any mechanism of acute marijuana toxicity on fetal or neonatal death.

It is nearly impossible to conduct prospective case control studies on adverse effects of marijuana use on maternal and fetal health during pregnancy. In the current social and cultural environment, even animal experiments on this topic are difficult. The most recent peer-reviewed publications were from 30 years ago. There has been no experimental data that show *in utero* fetal deaths resulting from maternal marijuana injection in large animals. Data relating most to human physiology was from an experiment on fetal disposition of marijuana during late pregnancy in the rhesus monkey [12]. This research demonstrates that marijuana rapidly crosses the placenta and enters the fetus. In the fetus, marijuana is concentrated in the liver/bile, adrenals, and thymus, as compared to the placenta, plasma, spleen, testes, lungs, brain, and kidneys [12]. These findings provide predictive data because of the numerous similarities between human and rhesus monkey pregnancy, including functional hemochorial placentas, single births, and comparable maternal/fetal weight ratios [12]. In addition, maternal high-dose marijuana injection could cause *in utero* fetal demise in small animals such as the rabbit, hamster, rat, and mouse [13–17].

Case Report

An 11-day-old white female neonate was pronounced dead at the hospital shortly after being found unresponsive at home. She was found unresponsive face-up and on her back by her mother. There is no evidence of suffocation due to unsafe sleep position or conditions. She was born at 36.5 weeks of gestation to a 20-year-old mother and appeared to be relatively healthy at the time of delivery. A complete autopsy and full investigation were conducted. Positive macroscopic findings included extensive hemorrhage of both adrenals (Figure 1), petechial hemorrhage of the entire liver (Figure 2), and focal hemorrhage of the thymus (Figure 3). X-ray revealed no fractures of any bones, and there was no evidence of trauma. Newborn screening of inborn errors of metabolism, and post-mortem neonate blood toxicology test, were both negative. The newborn drug screen of umbilical cord homogenate was conducted at the United States Drug Testing Laboratories (Des Plaines, IL, USA) and it revealed 528 pg/g carboxy-THC (screen cutoff at 50 pg/g). Microscopic examination of the liver (Figure 4) and adrenals (Figure 5) showed extensive necrosis and hemorrhage. There was focal hemorrhage of the thymus (Figure 6).

Indexed in: [PMC] [PubMed] [Emerging Sources Citation Index (ESCI)] [Web of Science by Clarivate]

Figure 1. Macroscopic examination of both adrenals, showing extensive hemorrhage. The arrows point to areas of severe hemorrhage.

Figure 2. Macroscopic examination of entire liver, showing petechial hemorrhage. The arrow points to one of the petechiae.

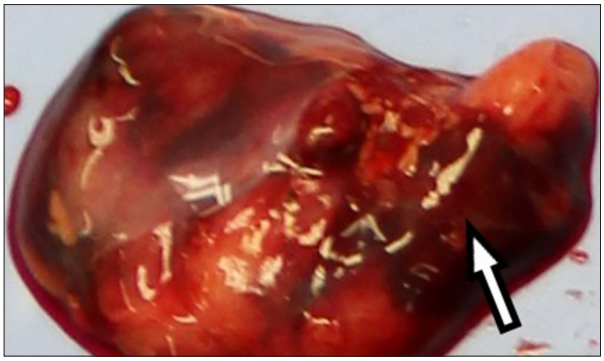

Figure 3. Macroscopic examination of thymus, showing focal hemorrhage. The arrow points to the center of one of the focal hemorrhages.

Microscopic examination of the other major organs were non-contributory, and there was no congenital disease or infection. The cause of death was extensive necrosis and hemorrhage of the liver and adrenals due to maternal use of marijuana. The maternal blood marijuana concentration, and pattern of marijuana use prior to and during pregnancy, are confidential at this time due to legal circumstances.

Indexed in: [PMC] [PubMed] [Emerging Sources Citation Index (ESCI)] [Web of Science by Clarivate]

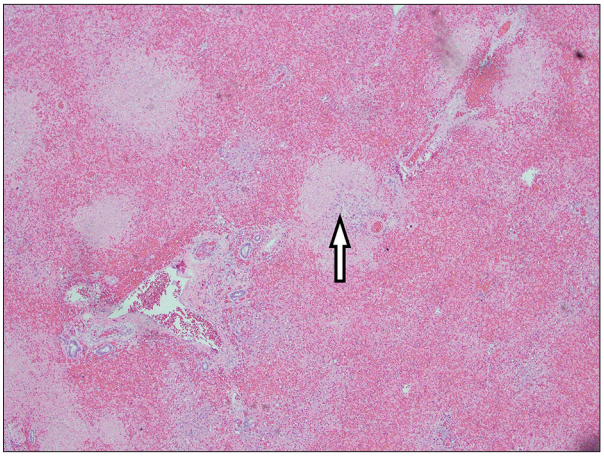

Figure 4. Microscopic examination of liver (hematoxylin and eosin, 40×) showing extensive necrosis and hemorrhage. The arrow points to the center of one area of necrosis. The hemorrhage is the background of the photo, consisting of red cells.

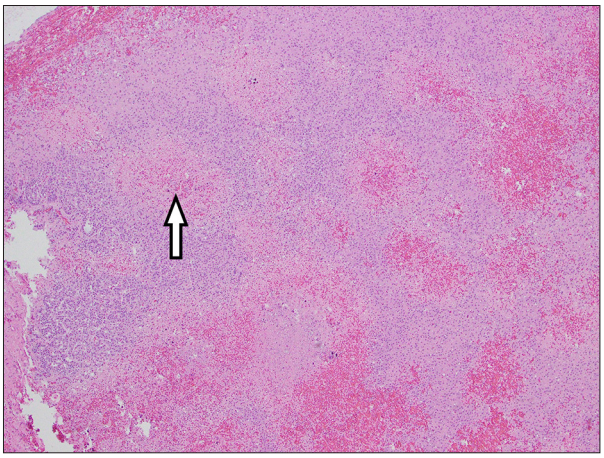

Figure 5. Microscopic examination of adrenal (hematoxylin and eosin, 40×) showing extensive necrosis and hemorrhage. The arrow points to the center of one area of necrosis and hemorrhage.

Discussion

The determination of the cause of death in this case was based on the forensic pathology principle of "diagnosis of exclusion". The neonate was unremarkable at delivery, and there was no congenital, metabolic, or infectious disease or trauma identified. Positive findings include necrosis and hemorrhage of the liver and adrenals, as well as focal hemorrhage of the thymus. The positive finding of marijuana in the umbilical cord provided evidence of maternal high-dose marijuana use in late pregnancy. Necrosis and hemorrhage of the liver and adrenals are consistent with animal data that show the concentration of marijuana in the liver/bile and adrenals after rapidly crossing the placenta. The thymus consists of mostly lymphoid tissues, which may resist necrosis and only show hemorrhage even with high-dose marijuana distribution.

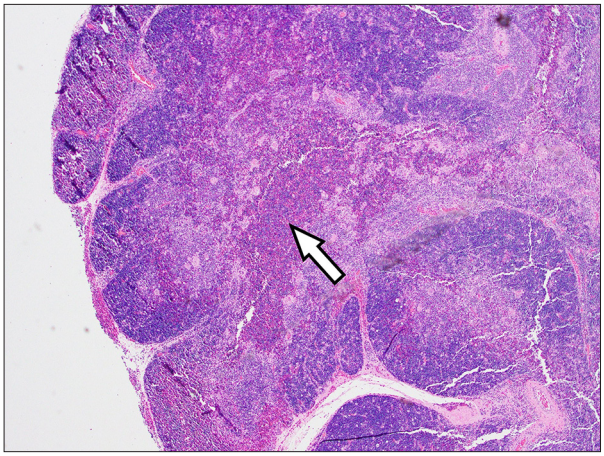

Figure 6. Microscopic examination of thymus (hematoxylin and eosin, 40×) showing focal hemorrhage without necrosis. The arrow points to the center of one area of focal hemorrhage.

This case is unique in that other possible causes of death can be eliminated. In cases of neonatal death with positive findings of multiple substances in the umbilical cord, or congenital, metabolic, or infectious disease, it is difficult to pinpoint maternal marijuana use as cause of death.

In the investigation of *in utero* fetal demise, it would be difficult to rule out maternal or placental factors even with positive findings of marijuana in the umbilical cord. In most autopsies of still-born fetuses, the internal organs are autolyzed, and it is difficult for pathologists to identify necrosis in the liver and adrenals.

Conclusions

In the last 5 years, the newborn drug screen of umbilical cord homogenate has been increasingly used by hospitals. With growing use of marijuana by pregnant women, more cases of neonatal death due to acute marijuana toxicity could be identified. Since prospective case control studies are almost impossible, retrospective review of case reports is the only way to identify acute marijuana toxicity in newborn health or death. Forensic pathologists have professional obligation to report these cases in peer-reviewed publications to inform the public for their "informed decisions" about marijuana use.

Conflict of interest

None.

Indexed in: [PMC] [PubMed] [Emerging Sources Citation Index (ESCI)] [Web of Science by Clarivate]

References:

1. Cohen K, Weinstein AM: Synthetic and non-synthetic cannabinoid drugs and their adverse effects – a review from public health prospective. Front Public Health, 2018; 6: 162
2. Abrams DI: The therapeutic effects of cannabis and cannabinoids: An update from the national academies of sciences, engineering and medicine report. Eur J Intern Med, 2018; 49: 7–11
3. Fischer B, Imtiaz S, Rudzinski K et al: Crude estimates of cannabis-attributable mortality and morbidity in Canada – implications for public health focused intervention priorities. J Public Health, 2015; 38: 183–88
4. Calabria B, Degenhardt L, Hall W et al: Does cannabis use increase the risk of death? Systematic review of epidemiological evidence on adverse effects of cannabis use. Drug Alcohol Rev, 2010; 29: 318–30
5. Foeller ME, Lyell DJ: Marijuana use in pregnancy: Concerns in an evolving era. J Midwifery Women's Health, 2017; 62: 363–67
6. Chabarria KC, Racusin DA, Antony KM et al: Marijuana use and its effects in pregnancy. Am J Obstet Gynecol, 2016; 215: 506.e1–e7
7. Metz TD, Allshouse AA, Hogue CJ et al: Maternal marijuana use, adverse pregnancy outcomes, and neonatal morbidity. Am J Obstet Gynecol, 2017; 217: 478.e1–e8
8. Committee on Obstetric Practice: Marijuana use during pregnancy and lactation. Obstet Gynecol, 2017; 130: e205–9
9. Conner SN, Carter EB, Tuuli MG et al: Maternal marijuana use and neonatal morbidity. Am J Obstet Gynecol, 2015; 213: 422.e1–e4
10. Warshak CR, Regan J, Moore B et al: Association between marijuana use and adverse obstetrical and neonatal outcomes. J Perinatol, 2015; 35: 991–95
11. Fergusson DM, Horwood LJ, Northstone K et al: Maternal use of cannabis and pregnancy outcome. Br J Obstet Gynaecol, 2002; 109: 21–27
12. Bailey JR, Cunny HC, Paule MG et al: Fetal disposition of THC during late pregnancy in the rhesus monkey. Toxicol Appl Pharmacol, 1987; 90: 315–21
13. Rosenkrantz H, Grant RJ, Fleischman RW et al: Marihuana-induced embryotoxicity in the rabbit. Fundam Appl Toxicol, 1986; 7: 236–43
14. Harbison RD, Mantilla-Plata B, Lubin DJ: Alteration of THC-induced teratogenicity by stimulation and inhibition of its metabolism. J Pharmacol Exp Ther, 1977; 202: 455–65
15. Fried PA: Short and long-term effects of pre-natal cannabis inhalation upon rat offspring. Psychopharmacology, 1976; 50: 285–91
16. Harbison RD, Mantilla-Plata B: Prenatal toxicity, maternal distribution and placental transfer of tetrahydrocannabinol. J Pharmacol Exp Ther, 1972; 180: 446–53
17. Geber WF, Schramm LC: Effect of marijuana extract on fetal hamsters and rabbits. Toxicol Appl Pharmacol, 1969; 14: 276–82

Indexed in: [PMC] [PubMed] [Emerging Sources Citation Index (ESCI)] [Web of Science by Clarivate]